

VIVEKANANDA COLLEGE
THAKURPUKUR
KOLKATA-700063
NAAC ACCREDITED GRADE—'A'



TOPIC: LUNGS AND AIR SACS IN BIRDS

TITLE: COMPARATIVE ANATOMY OF VERTEBRATES

PAPER: CC8 (ZOOA-CC4-8-TH)

UNIT: 3

SEMESTER: IV

NAME OF THE TEACHER: RANU CHAKRAVARTY

NAME OF THE DEPARTMENT: DEPARTMENT OF ZOOLOGY.

LUNGS AND AIR SACS IN BIRDS (*Columba* sp.)

The aerial mode of life requires extra energy. The intense activity of flight demands large supplies of oxygen, as the respiratory system of birds is more complicated than of any other vertebrate. Respiration is pulmonary and the respiratory organs are fairly simple.

Unique features:

- A true muscular diaphragm is absent in birds and the expansion of the thoracic wall is limited.
- The lungs are relatively small and compact organs, continued into a unique system of air sacs.
- The expiration is more active process than inspiration.

Components of respiratory system: The respiratory system includes

- ✓ the respiratory tract,
- ✓ the respiratory organs or the lungs and
- ✓ the air sacs.

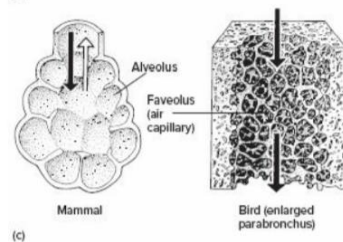
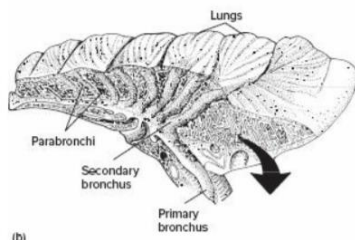
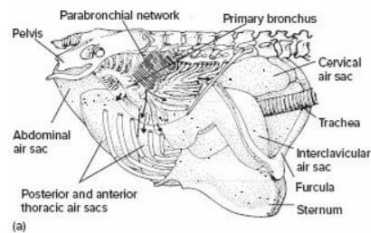
Respiratory tract: It includes

1. **Nares:** The nostrils or **external nares** are a pair of slit-like oblique openings lying at base of the upper beak, overlapped by a swollen sensitive pad of skin, the cere or operculum. The nostrils lead into short olfactory or nasal sacs, which open directly into the pharynx by **internal nares**.
2. **Glottis:** This is a slit-like aperture, which is present on the floor of the mouth cavity and near the base of the tongue. It leads into the next part called trachea.
3. **Trachea:** At its anterior end, the trachea has an expanded voiceless chamber, **the larynx**. It is greatly reduced in birds. It is supported by a **cricoid cartilage** composed of four pieces, and by paired **arytenoid cartilages**. But the thyroid cartilage and the vocal cords, so that larynx does not produce sound in birds. The trachea is a long, cylindrical and flexible tube running back through the neck, ventral to the oesophagus, but is displaced to the left in the middle region by the crop. On entering the thoracic cavity, it expands into a syrinx and then bifurcates into two short bronchi, one for each lung. The trachea and the bronchial tubes are supported by a series or closely-set rings. All the tracheal rings and the first bronchial rings are complete and bony; the rest of the bronchial rings are incomplete medially and cartilaginous.
4. **Syrinx:** At the posterior end or base of the trachea, at its junction with the bronchi, is found a special structure, the syrinx or voice box, concerned with sound production. Syrinx consists of an expanded chamber, called tympanum, the walls of which are supported by the last three or four rings of trachea and the first half ring of each bronchus. At the junction of the two bronchi a bony ridge, the pessulus, extends dorsoventrally. It supports a small, vibratory crescentic or semilunar membrane. The inner membranous lining of the bronchi produces inconspicuous internal tympani-form membranes. Sound is produced by the vibration of the semilunar membrane while the pitch of the sound is controlled by the action of the syringeal musculature.

Respiratory organ or Lungs:

- The lungs of pigeon are bright red, small, compact, slightly distensible, being solid, spongy, highly vascular organs.
- They differ from those of other vertebrates in that they do not store air.

- **Location:** They lie in the pleural cavities which are separated from the peritoneal or abdominal coelom by an oblique septum.
- **Structure:**
 - They do not hang freely in thoracic cavity, but are closely applied by their dorsal surface to thoracic vertebrae and the ribs. Dorsally, they have no peritoneal covering. The ventral surface is free and covered by a thick sheet of fibrous tissue, the pleura or pulmonary **aponeurosis**, a special development of the peritoneum.
 - Small fan-like **costo-pulmonary or inter-costal muscles**, which arise from the junction of the sternal and vertebral ribs, are inserted in the pleural covering.



Avian lung. (a) Right, lateral view

(b) Right, lateral view. The isolated lung is sectioned. The small pores in the exposed lung are parabronchi.

(c) Comparison of mammalian and avian respiratory surfaces. In the mammalian lung, the alveoli are blind-ended.

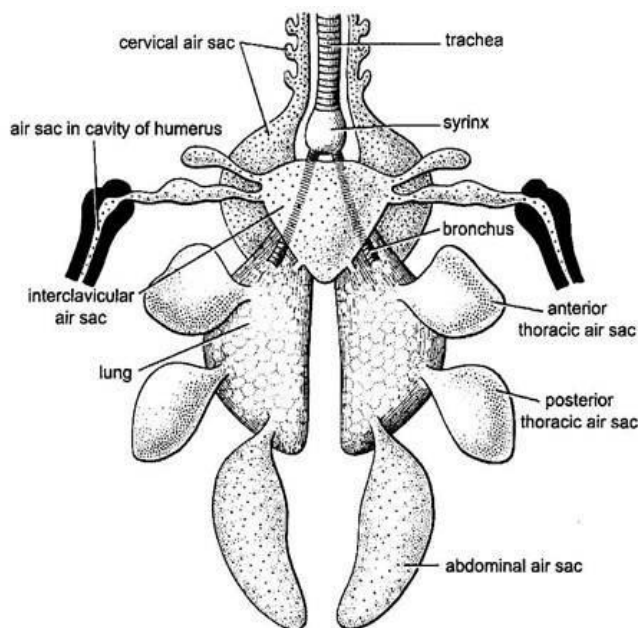
- **Structure of bronchus:** The antero-ventral end of each lung is pierced by a bronchus termed as primary bronchus in birds.
 - **Primary bronchus:** Within the lung it loses its cartilaginous rings, reaches up to its distal or posterior end, and becomes the mesobronchus.
 - **Secondary bronchus:** The mesobronchus branches into air sacs and also gives off secondary bronchi. According to their position which may be distinguished as dorsal, ventral and lateral.
 - **Parabronchi:** The dorsal and the ventral secondary bronchi branch again into many tertiary bronchi or parabronchi.
 - **Air capillaries:** The parabronchi give rise to an intricate system of ramifying and anastomosing fine, thin-walled tubules or air capillaries, forming loops and forming the main substance of the lungs. Each air capillary opens at both the ends into a parabronchus. There are no alveoli and hence no air capillaries end blindly. As a result there is no dead space in lungs, through which air does not flow.
 - **Lung parenchyma** shows hexagonal areas or units, each containing of a central parabronchus, surrounded by a system of associated air capillaries with interlacing blood capillaries. The inner vascular surfaces of air capillaries serve as respiratory membranes through which gaseous exchange with blood takes place.

Air sacs:

Air sacs are large, thin-walled, membranous, non-muscular and non-vascular sacs around the lungs and connected with the ends of the main bronchial branches. They are formed by the dilation of mucous membrane of bronchus. They lie among the viscera and even extend into some of the larger bones. Their total volume is several times than that of the lungs and they fill up much of the body cavity. **They arise from the secondary bronchi except the abdominal air sac that arises from the posterior end of the mesobronchus.** Openings of bronchi into air sacs are called ostia. All air sacs remain in communication with the pneumatic cavities of the bones. Except the cervical air sacs, all others air sacs rejoin the bronchi through the recurrent bronchi or the saccobronchi.

There are nine (9) major and four (4) accessory air- sacs in pigeon:

- **Major air sacs:** The major air-sacs originate directly from the lungs. Of the nine air-sacs, four are paired and one is unpaired:
 - (a) **Paired air-sacs:**
 - (i) Posterior or abdominal air-sacs.
 - (ii) Posterior thoracic air-sacs.
 - (iii) Anterior thoracic air-sacs.
 - (iv) Cervical air-sacs.
 - (b) **Unpaired air-sac:**
 - (i) Inter-clavicular or median air-sac.
- **Accessory air-sacs:** These air-sacs originate as paired diverticula from the inter-clavicular air-sac. These paired sacs are:
 - (i) Clavicular air-sacs, and
 - (ii) Humeral air-sacs.



Lungs and air sacs in *Columba* sp

Major air sacs	Description	Location
Interclavicular (Unpaired)	It is a single median and somewhat triangular air sac, connected with both lungs. On either side, it gives off an axillary or extra-clavicular sac in the arm-pit, communicating with an air-cavity of the humerus, and a clavicular sac.	It is situated in the angle between the two limbs of the furcula
Cervical (Paired)	A pair of small cervical sacs arises anteriorly, one from each lung. They give off minor saccules in the neck	They lie at the base of the neck, dorsal to the interclavicular and alongside the vertebral column.
Anterior thoracic (Paired)	A pair of anterior thoracic air sacs. They extend back so as to overlap the posterior thoracic air sacs.	They lie ventral to the lungs in the anterior part of the chest, in close contact with the ribs and the pericardium.
Posterior thoracic (Paired)	The pair of small posterior thoracic air sacs overlap the posterior end of its lung and communicates with its outer posterior angle. The left sac is slightly larger than the right.	It is found in the posterior part of the thoracic cavity, just in front of the abdominal air sacs.
Abdominal (Paired)	A large posterior or abdominal air sac arises from the outer posterior angle of each lung.	They lie along the dorsal wall of the abdomen, ventral to the kidneys, amongst the coils of the small intestine.

A layer of fibrous tissue called oblique septum encloses the ventral walls of both the thoracic air-sacs. This septum extends up to the pericardium and unites with the similar septum of the other side. Such union along the middle line separates the body cavity into two chambers. One chamber houses the lungs, thoracic and inter-clavicular sacs and the other chamber contains the heart, liver, stomach, intestine and abdominal air-sacs.

- **Functions of air sacs:** The air sacs communicate with bronchi on the one hand, and with the pneumatic cavities of the bones, on the other hand. The following functions have been attributed to them.
 - (a) Function as bellows: As the lungs are anchored firmly to the dorsal wall of the thoracic cavity, the elasticity of the lungs is greatly hampered. To carry on an efficient circulation of air through lungs during respiration, some mechanical aid becomes necessary, specially during flight. The air-sacs give mechanical aid by acting as the bellows.
 - (b) Lightness: They act as balloons to provide lightness and buoyancy to the body, by reducing the specific gravity of the body.
 - (c) Flight: Their association with flight is also confirmed by the fact that the best fliers amongst birds possess the most highly developed air sacs.
 - (d) Accessory respiratory organs: The sacs function principally as the accessory breathing organs. Their smooth lining is devoid of capillaries and does not take part in gaseous exchange. But they serve as reservoirs and take part in the movements of air during respiration. They take care of the residual (dead) air, thus ensuring a complete renewal of air in the lungs at each breath. At each expiration, they act as bellows forcing their air out through the lungs, thus leaving no dead space or unrespired air in the lungs.
 - (e) Temperature regulation: They may also aid as cooling devices in the regulation of the temperature of the body, thereby compensating for lack of sweat glands. It occurs by

internal perspiration i.e., water vapours diffuse from blood into the cavities of air sacs and pass out through the lungs, accompanied by loss of body heat.

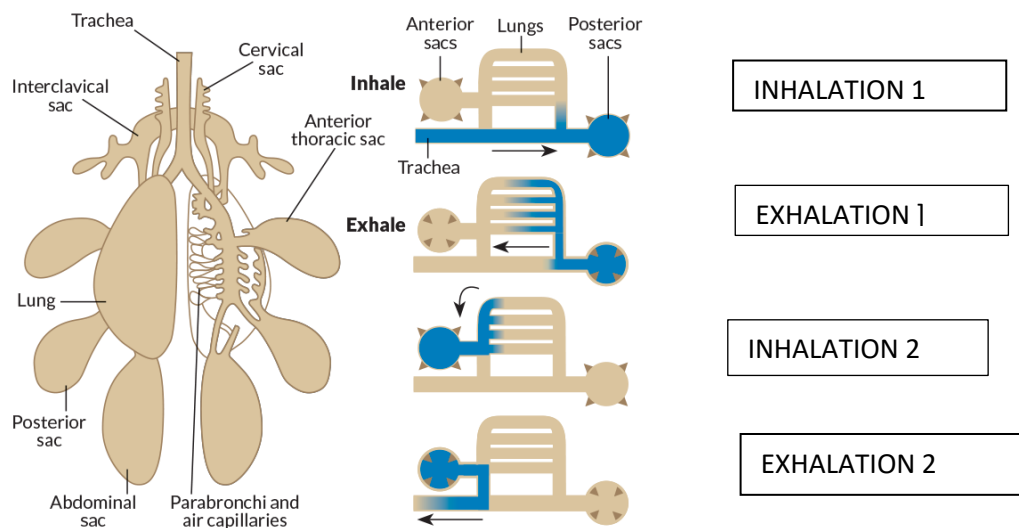
- (f) Cardiac movements: Another probable function of air sacs, according to Muller (1908), appears to allow for the movement of the heart in an otherwise very rigid thorax.
- (g) Functions as ballast: Air sacs are arranged nicely on the two sides of the body so that the proper center of gravity is maintained for the flight. If somehow the equilibrium is altered, it is restored by shifting the contained air from one side of the body to another.
- (h) Minimized mechanical friction: Air sacs and its bronchus are inserted between muscles like pads which reduces mechanical friction during flight.
- (i) Resonator: Air sacs help in forceful expulsion of air and controls the pitch of sound thus, act as resonator.

• **Physiology and Mechanism of Respiration:**

The avian respiratory system includes anterior (interclavicular and anterior thoracic) and posterior (posterior thoracic and abdominal) air sacs that connect to the parabronchial network and hence to the respiratory tissue.

Airflow patterns during breathing: Movement of one draft of air in, through, and out requires two cycles of inhalation/exhalation.

- ✓ During the inhalation (1), the draft of air (solid arrow) enters and is divided, with some filling the posterior air sacs and the rest passing to the parabronchial network.
- ✓ Upon exhalation (1), fresh air from the posterior air sacs passes into the lungs, pushing spent air out.
- ✓ The second breath/inhalation (dashed arrow) of inhalation (2) enters and is divided, with some refilling posterior air sacs and the rest passing to the parabronchial network, pushing the remainder of the air from the first breath into the anterior air sacs.
- ✓ During second exhalation (2), spent air is pushed out of the lungs and exits with air from the anterior air sacs.



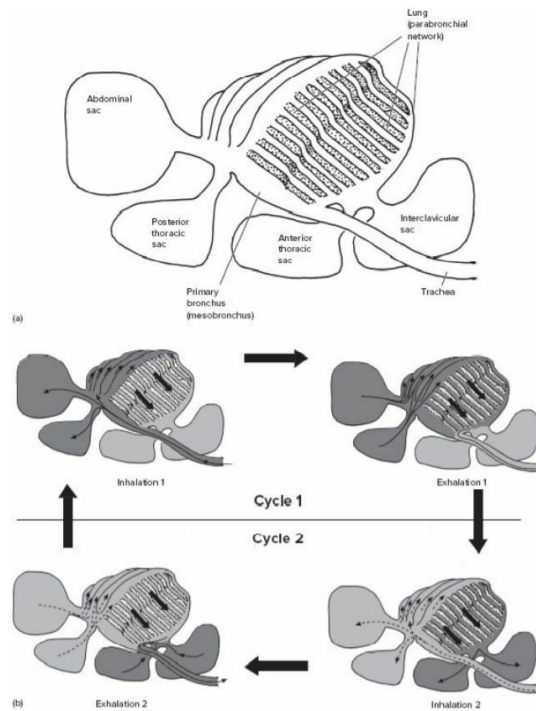


FIG: Schematic representation of lung ventilation in birds.

Respiratory mechanism:

The breathing mechanism is like that of a suction pump, and differs at rest from that during flight.

1. **Ventilation at rest:** When the bird is resting, its sternum rises and falls alternately by the activity of abdominal and intercostal muscles.
 - a. During inspiration, the sternum is lowered, the air sacs expand and the lungs are compressed. As a result, fresh, air moves through nostrils, trachea and mesobronchus into the posterior air sacs. At the same time, air already present in the lungs moves to the anterior air sacs.
 - b. During expiration, the sternum is raised, the air sacs compressed and the lungs expand. Air high in O₂ content moves from posterior air sacs into the lungs, and the stale air of anterior air sacs moves into the mesobronchus, the trachea, then out through the nostrils.
2. **Ventilation during flight:** During flight, the sternum is rendered immovable and the air goes in and out of the lungs by the elevation and depression of the back, synchronized with the strokes of the wings. The faster a bird flies, the more rapid is the air circulation and gaseous exchange in the lungs.

Efficiency of avian lungs

The presence of anastomosing and intercommunicating air capillaries in avian lungs, accompanied by the presence of air sacs, brings about several advantages:

- (1) There is a one-way flow of air through the air capillaries. The direction of air in lung is counter to that of the blood flow, as also found in the gills of many fishes.
- (2) The inspired air rushes through the lungs into the air sacs and thence into the pneumatic cavities of the bones. Unlike other vertebrates, the avian lung, therefore, is completely emptied at each breath. There is no dead space in the lungs, the residual air being confined to the air sacs.

(3) Moreover, the air of lungs is renewed twice at every breath, once during inspiration and again during expiration.

(4) The air does not travel back during expiration through the same route by which it entered during inspiration. Most air reaches the air sacs directly through the secondary bronchi. But from air sacs it goes back into the lungs through separate ducts, called the recurrent bronchi.

(5) The respiratory rate of birds is also very high. In pigeon, it is 29 times per minute at rest, as contrasted with 14 to 20 times per minute in man. As the air passes over the respiratory epithelium rapidly and several times, the aeration of blood is very complete in birds and their body temperature is relatively higher than that of other vertebrates. Their body temperature varies from 40.5°C (105°F) to as high as 46°C (115°F).

This explains how the small and non-elastic avian lungs function more efficiently than those of other vertebrates, in spite of the fact that birds have the highest oxygen requirements of all animals because of their active mode of life and high metabolic rate.

R Chakravarty