

VIVEKANANDA COLLEGE

THAKURPUKUR

KOLKATA-700063

NAAC ACCREDITED 'A' GRADE



TOPIC: **IDENTIFICATION OF BLOOD CELLS FROM HUMAN BLOOD.**

COURSE TITLE: **ANIMAL PHYSIOLOGY: LIFE SUSTAINING SYSTEMS.**

PAPER: **CC9**

UNIT: **PRACTICAL**

SEMESTER: **4**

NAME OF THE TEACHER: **DR. SENJUTI ROY MUKHERJEE**

NAME OF THE DEPARTMENT: **ZOOLOGY**

## INTRODUCTION

Blood is a complex fluid consisting of plasma—extracellular fluid rich in proteins and of formed elements—red blood cells (RBCs), white blood cells (WBCs), and platelets. Total blood volume is ~70 mL/kg body weight in the adult woman and ~80 mL/kg body weight in the adult man.

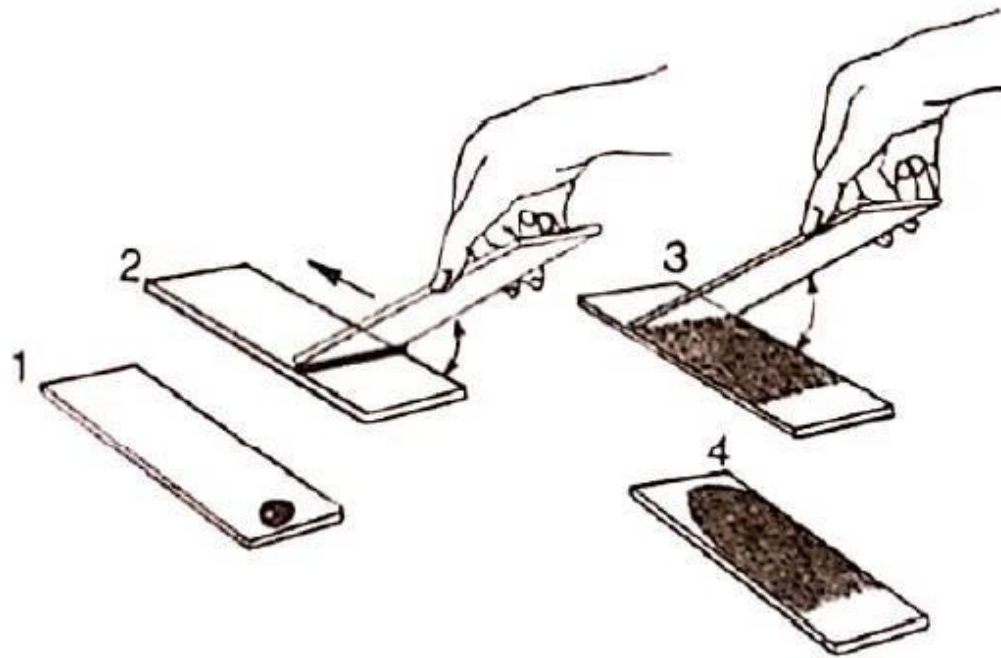
If a drop of blood is spread thinly on a glass slide, the cellular elements of blood can be detected. In such a **peripheral blood smear**, the following mature cell types are easily recognized: erythrocytes, granulocytes (divided into neutrophils, eosinophils, and basophils), lymphocytes, monocytes, and platelets.

## **MATERIALS REQUIRED**

i) Glass slides, ii) Rectified spirit, iii) Sterilized needle, iv) Cotton, v) Leishman stain, vi) Distilled water, vii) Pasteur pipette and viii) Compound microscope.

## **PROCEDURE**

- 1) Two clean grease-free slides are taken.
- 2) Tip of middle finger is cleaned with rectified spirit soaked cotton and pricked with a sterilized needle.
- 3) The first drop of blood is wiped away with cotton. The second drop of free flowing blood is taken on the clean slide about 1 cm from the right narrow edge of it.
- 4) The smooth narrow edge of the second slide is put on the first one making an angle of  $45^\circ$  just left to the drop of blood.
- 5) The second slide is slowly pulled, holding in position, to the right until it touches the drop of blood. Immediately, the second slide is pushed to the left at uniform speed. Such leftward movement of the second slide makes a thin tongue-shaped blood film.
- 6) The smear is air-dried.
- 7) Then the slide is taken in a Petri dish and the smear is totally covered with appropriate quantity of Leishman stain. The Petri dish is covered and left for 5 minutes.
- 8) An equal amount of distilled water is put on the stain carefully and after proper mixing of the stain and water the slide is again kept covered for 5 minutes.
- 9) The slide is drained off and washed with water and dried in air.
- 10) The slide is observed under microscope.



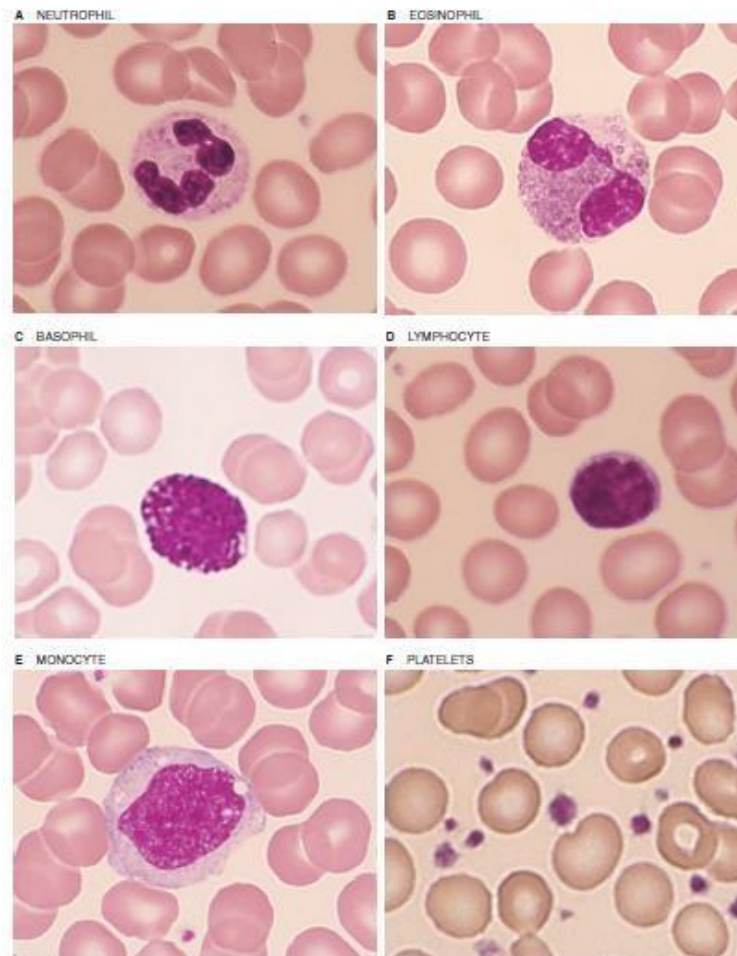
**Fig 1. Steps of preparation of blood film**

## **OBSERVATION**

- The peripheral blood smear shows the following mature cell types: Red Blood Cell (RBC)
- Most abundant (average 5.5 million/mm<sup>3</sup> in males & 4.8 million/mm<sup>3</sup> in females).
- They are circular, anucleated biconcave discs.
- Diameter of each RBC is 7.2 μm (range 6.9 -7.4 μm)
- Thickness in the periphery is 2 μm and in the centre is 1 μm. White Blood Cell (WBC)
- The leukocytes are of two main varieties: granulocytes and nongranulocytes.
- Depending on the colour of granules, granulocytes are divided into three types : Neutrophils, Eosinophils and Basophils
- The nongranulocytes are of two types: Lymphocytes and monocytes.
- The total leukocyte count is 4000 – 11,000/mm<sup>3</sup> of blood.
- The WBCs are identified by their granule content, cell size, shape and number of nuclear lobes. Platelet (Thrombocyte)
- 150,000 to 450,000 platelets per microliter of blood.
- Smallest blood cells with 2 to 4μm diameter.
- Spherical or oval discoid in shape.
- Leishman staining shows faint bluish cytoplasm containing reddish-purple granules.
- Nucleus is absent.

Name of leucocytes	Identifying hallmarks			
	Diameter ( $\mu\text{m}$ )	Cytoplasmic granules	Nuclear shape	Specialities
Neutrophils	09–12	Fine granules (violet)	Divided into 3 to 4 lobes with fine strands of cytoplasm.	Young cells sometimes possess undivided nucleus.
Eosinophils	10–14	Course granules (rosy)	Bilobed nucleus.	Bilobed nucleus appears as if two balloons are tied together.
Basophils	08–10	Course granules (purple)	S or U-shaped nucleus.	Nucleus is made obscure from view by course granules in cytoplasm.
Lymphocytes	5–8 (small) 10–12 (medium) 14–17 (large)	—	Large nucleus; almost fills the cell leaving only a narrow rim of cytoplasm.	Many intermediate forms are possible; light microscopic study appears difficult.
Monocytes	12–15	—	Round/oval/lobed/kidney shaped/C-shaped; cytoplasm is abundant and clear.	Largest of all leucocytes; usually twice the size of erythrocytes.

Table 1. Identifying characters of White Blood Cells of human



Peripheral blood smear showing the different cell types.

Fig 2.

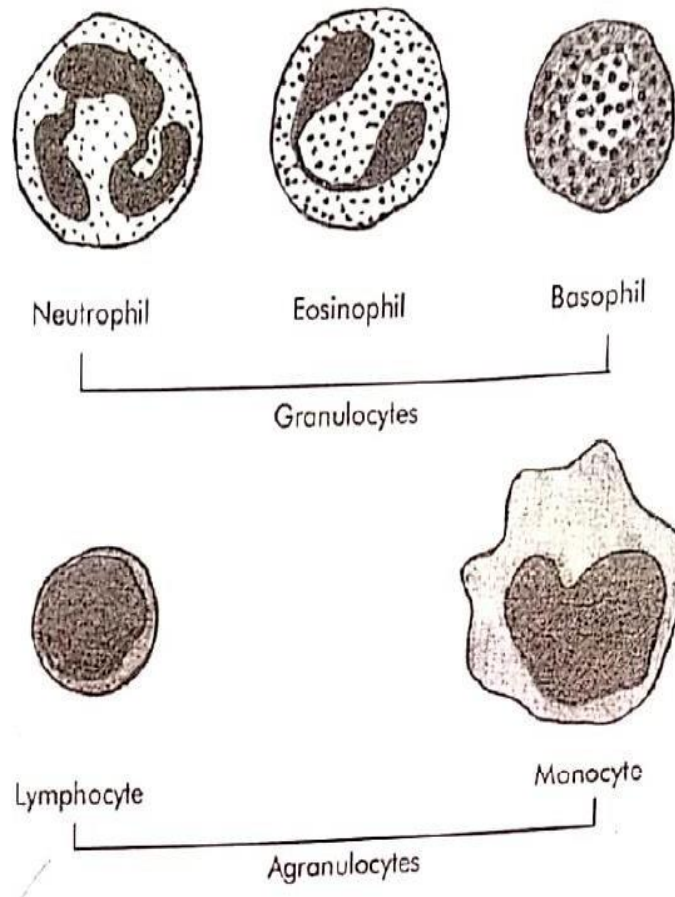


Fig 3. Diagrammatic representation of different WBCs in human

## **PRECAUTIONS**

- The smear should be made immediately after blood is collected by finger puncture.
- While making the smear, proper positioning of the slides must be
- Care should be taken that Leishman covers the entire smear and the stain should not dry up.
- While mixing distilled water with Leishman stain, the pasteur pipette should be used very carefully to avoid scratch on the smear.

## NOTES TO STUDY

- If a sample of blood containing anticoagulant is spun down for 5 minutes at 10,000g, the bottom fraction contains **formed elements** – RBCs (or erythrocytes), WBCs (or leukocytes, which include granulocytes, lymphocytes and monocytes) and platelets (thrombocytes); the top fraction is blood plasma. The RBCs having the highest density are at the bottom of the tube, whereas most of the WBCs and platelets form a whitish gray layer—the **buffy coat**—between the RBCs and plasma. Only a small amount of WBCs, platelets, and plasma is trapped in the bottom column of RBCs.
- **Hematopoiesis** is the process of generation of all the cell types present in blood. Blood cells are produced in the bone marrow. **Erythropoietin (EPO)**, is produced by the kidney and to a lesser extent by the liver. This cytokine supports erythropoiesis or red cell development.

## **NOTES TO STUDY**

- Biconcavity of RBCs make them quite flexible so that they can pass through narrow capillaries. Biconcavity also provides greater surface area as compared to volume, so the RBC can withstand considerable changes of osmotic pressure.
- The differential leukocyte count (DLC) is an excellent indicator of any pathological change of the body.
- Leukocytosis refers to increase in total WBC count while leukopenia refers to decrease in total WBC count.
- Phagocytosis refers to the process of engulfment and destruction of solid particulate material by the cells. Neutrophils, monocytes and tissue macrophages can act as phagocytes.
- Leukemias constitute a group of malignant diseases of the blood in which there occurs an increase in the total WBC count associated with the presence of immature WBCs in peripheral blood.
- Platelets do not have nucleus, so they cannot reproduce.